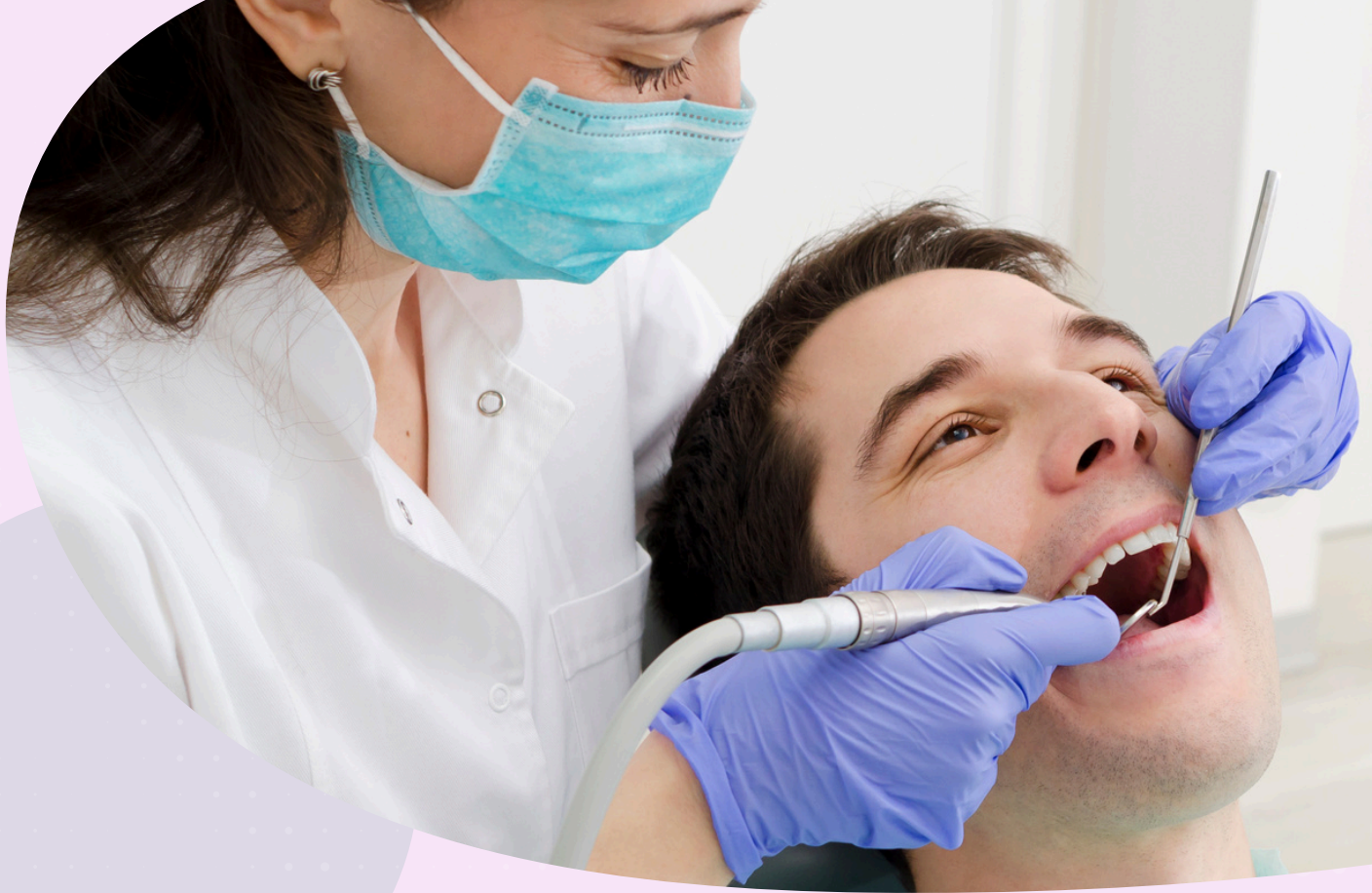



48

Dental Charting

Symbol And Meaning

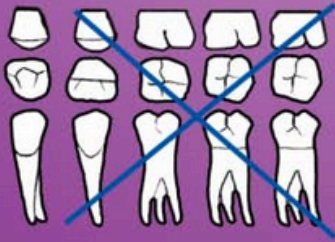


Symbol 

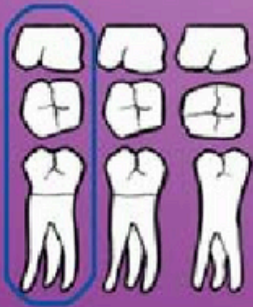
Table Of Contents

No	Name	Page
1	Multiple missing teeth	1
2	Teeth impacted or unerupted	1
3	Teeth that are drifting/mesial inclination	1
4	Teeth that are drifting/overerupted	1
5	Teeth to be extracted	2
6	All teeth missing	2
7	Tooth with root canal treatment, apicoectomy, and silver amalgam retrofilling	2
8	Teeth that are drifting/distal inclination	2
9	Teeth that need root-canal therapy	3
10	Tooth with a completed root canal	3
11	Tooth with 3/4 gold crown	3
12	Tooth with a DO inlay crown	3
13	Tooth with an abscess	4
14	Tooth with full gold crown	4
15	Tooth with an MOD onlay crown	4
16	Tooth with a porcelain crown	4
17	Tooth with a porcelain fused to metal crown	5
18	Fixed bridge	5
19	Supernumerary tooth	5
20	Periodontal pocket	5

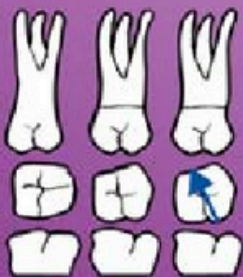
21	Fixed bridge (abutment 3/4 gold crown-pontic-full gold-abutment full gold)	6
22	Maryland bridge	6
23	Tooth with a temporary restoration	6
24	Overhang on a restoration	6
25	Food impaction	7
26	Decalcification	7
27	Mesio-occluso-distal (MOD) amalgam restoration with recurrent decay	7
28	Occlusal amalgam restoration	7
29	Open contacts	8
30	Heavy Calculus	8
31	Occlusal caries	8
32	Occlusal composite restoration	8
33	Partial denture	9
34	Fractured tooth or fractured root	9
35	Rotated tooth	9
36	Stainless-steel crown	9
37	Full denture	10
38	Dental implant	10
39	Diastema	10
40	Porcelain veneer	10



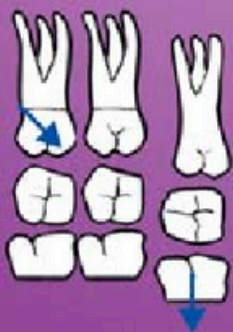
Multiple missing teeth



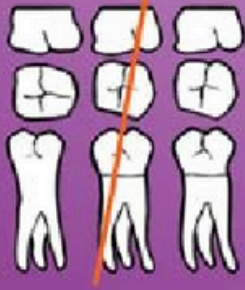
Teeth impacted or unerupted



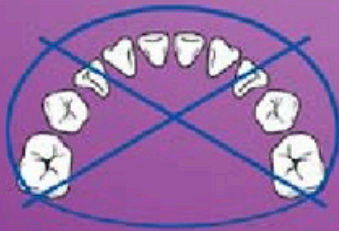
Teeth that are drifting/
mesial inclination



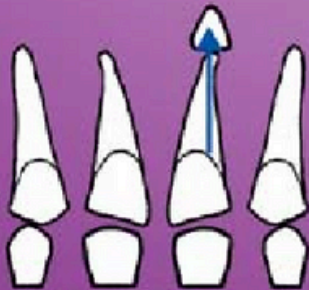
Teeth that are drifting/
overerupted



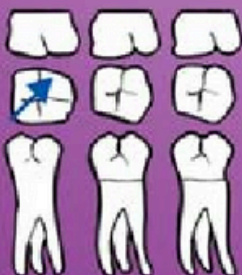
Teeth to be extracted



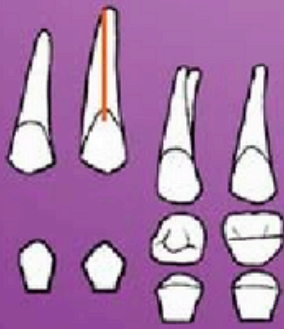
All teeth missing



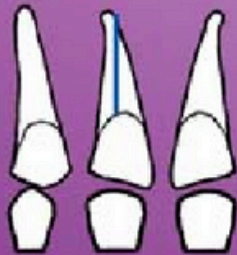
Tooth with root canal treatment, apicoectomy, and silver amalgam retrofilling



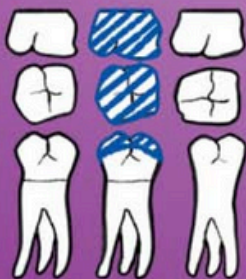
Teeth that are drifting/
distal inclination



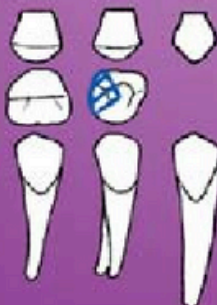Teeth that need root-canal therapy



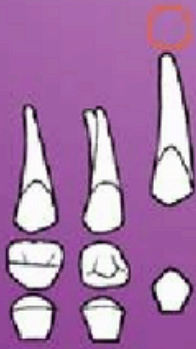
Tooth with a completed root canal



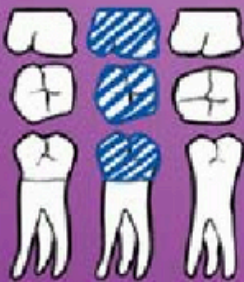
Tooth with 3/4 gold crown



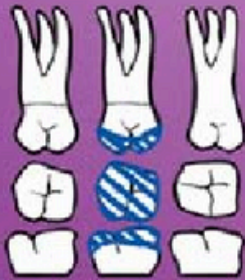
Tooth with a DO inlay crown



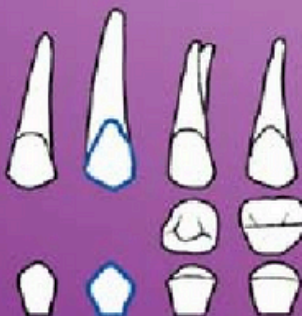
Tooth with an abscess



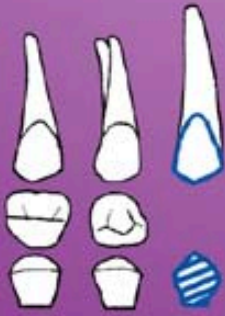Tooth with full gold crown



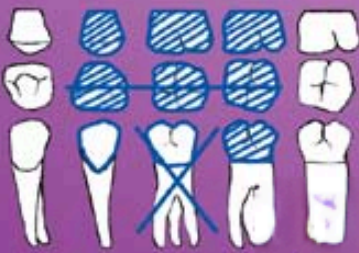
Tooth with an MOD onlay crown



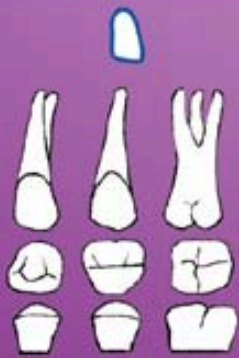Tooth with a porcelain crown



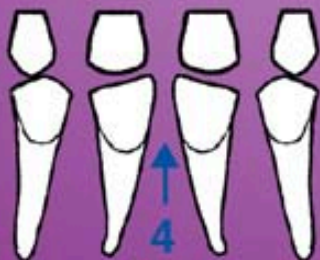
Tooth with a porcelain fused to metal crown



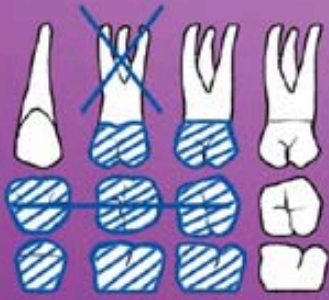
Fixed bridge (porcelain fused to metal abutment-pontic-porcelain fused to metal-abutment full gold crown)



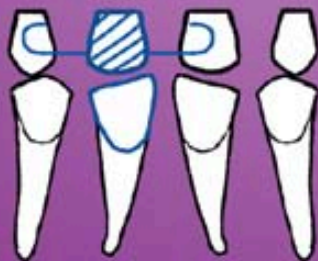
Supernumerary tooth



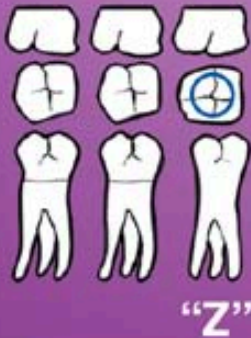
Periodontal pocket



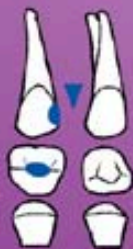Fixed bridge (abutment
3/4 gold crown-pontic-full
gold-abutment full gold)



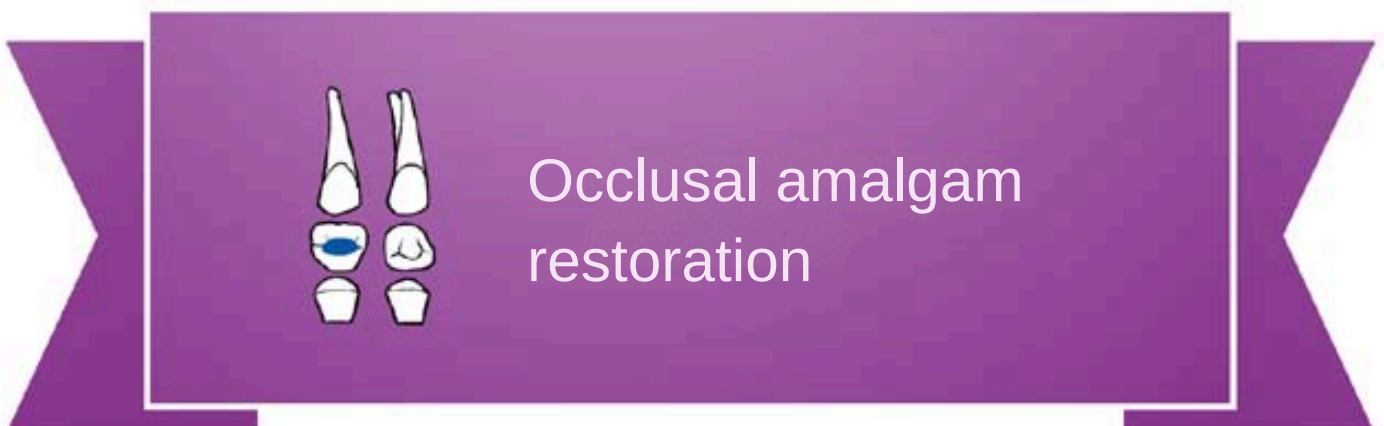
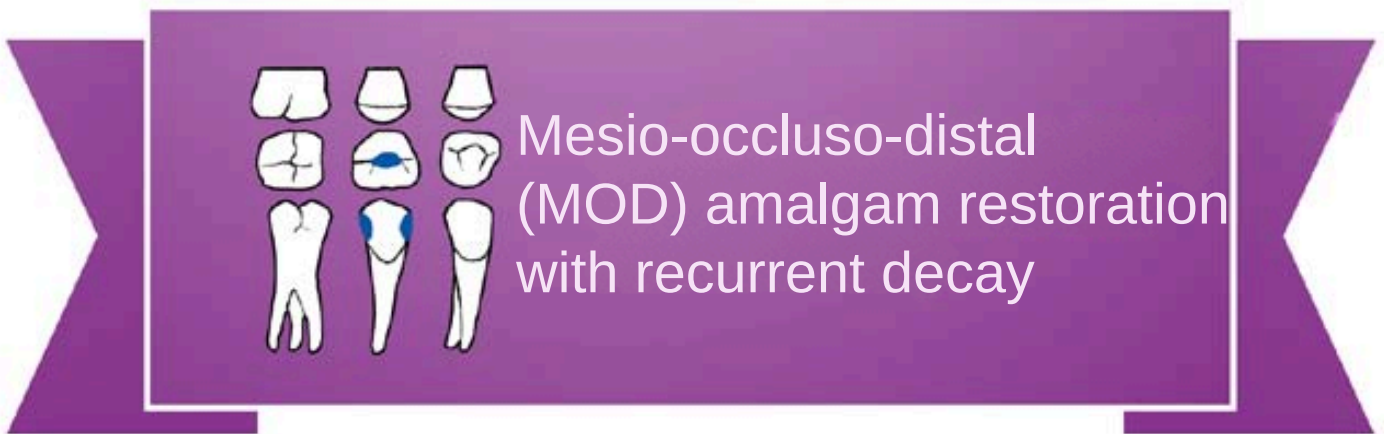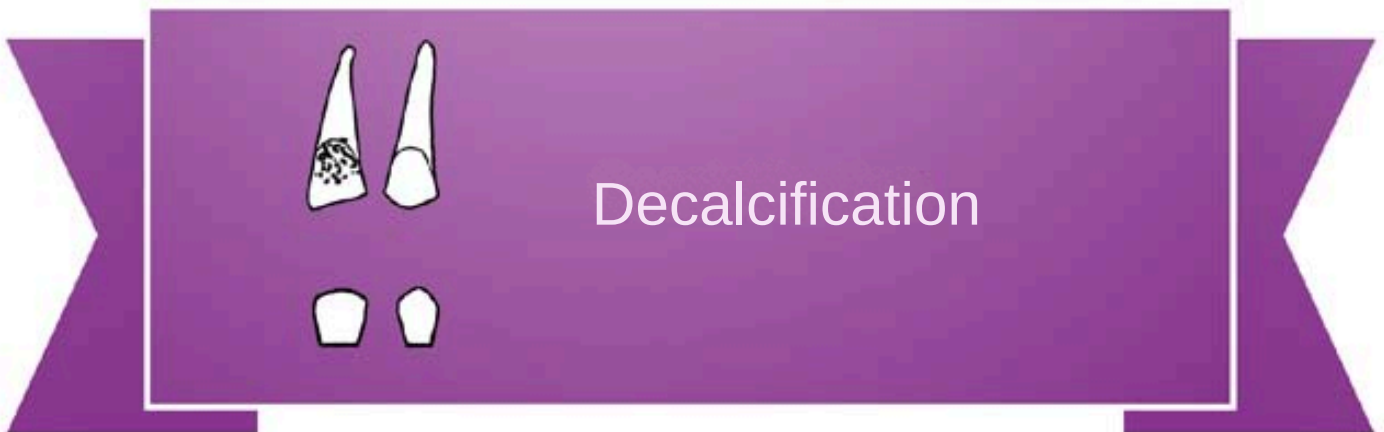
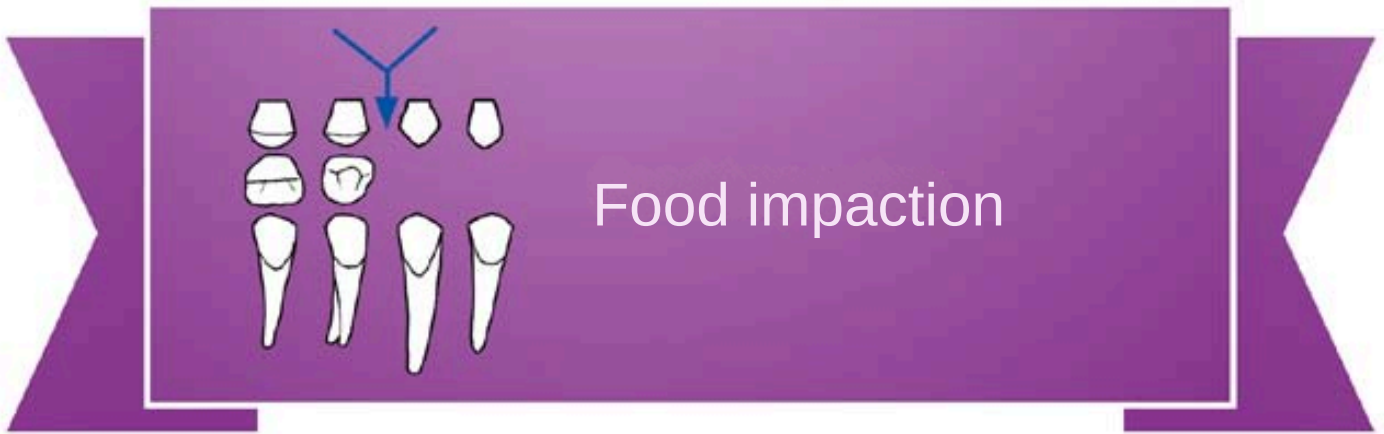Maryland bridge

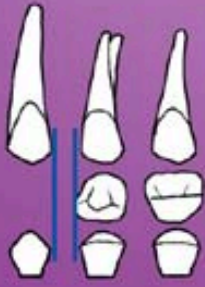

Tooth with a temporary
restoration

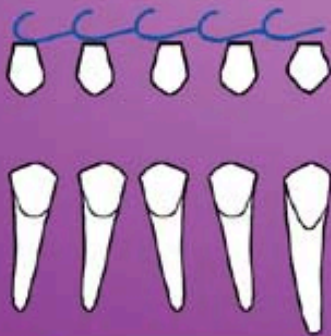


Overhang on a restoration

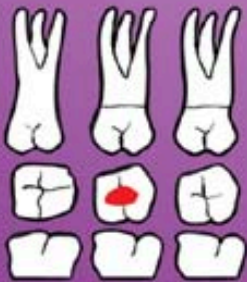




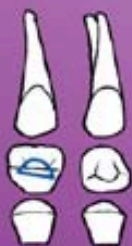Open contacts



Heavy Calculus

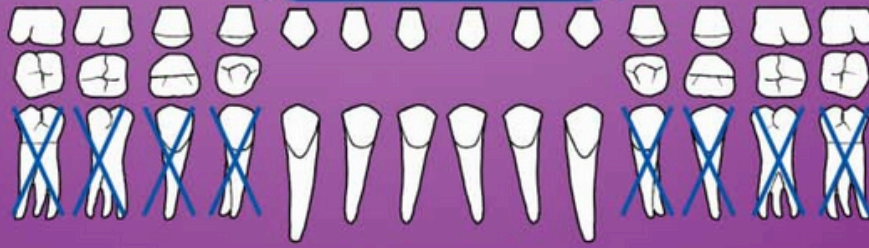


Occlusal caries

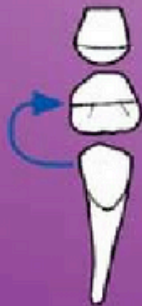

Occlusal composite
restoration

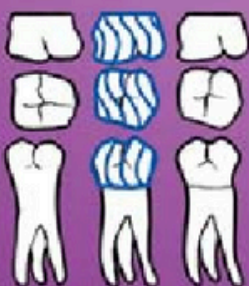Partial denture



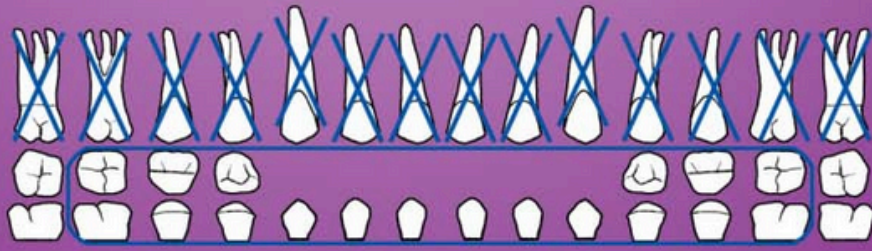
Fractured tooth or
fractured root



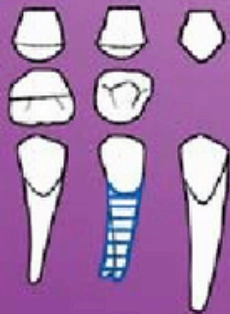
Rotated tooth



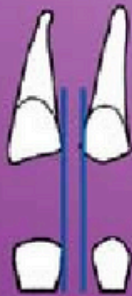Stainless-steel crown



Full denture



Dental implant



Diastema



Porcelain veneer